



Combined spinal-epidural anesthesia in a patient with spinal muscular atrophy type II undergoing a cesarean section: A case report

Kombinovana spinalna-epiduralna anestezija za carski rez kod porodilje sa spinalnom mišićnom atrofijom tip II

Slavica Krušić*, Branka Nikolić*[†], Rastko Maglić*[†]

*Obstetrics and Gynecology Clinic “Narodni front” Belgrade, Serbia;
University of Belgrade, [†]Faculty of Medicine, Belgrade, Serbia

Abstract

Introduction. Anesthetic management of a patient with spinal muscular atrophy type II, who underwent elective cesarean section with neuraxial anesthesia is presented in this case report. **Case report.** A 33-year old woman with first pregnancy and no previous birth, at 39 weeks gestational age was scheduled for a cesarean section due to placenta *previa*. She had a history of spinal muscular atrophy type II, that confined her to a wheelchair, and a surgical history that included corrective surgery for kyphoscoliosis. The patient had predictors for a difficult intubation (limited mouth opening and reduced neck extension) so the decision was made to attempt the needle-through-needle combined spinal-epidural technique for surgical anesthesia. Harrington rods and scar tissue complicated placement of the combined spinal-epidural anesthesia, however successful placement was achieved. **Conclusion.** Spinal muscular atrophy in pregnancy is rare and represents big challenge for an anesthesiologist due to respiratory dysfunction, anticipated difficult intubation, severe kyphoscoliosis and limitations of the use neuromuscular blocking agents. The potential risks need to be considered when administering anesthesia in patients with spinal muscular atrophy undergoing a cesarean section.

Key words:
labor; cesarean section; myotonic disorders;
anesthesia, epidural; anesthesia, spinal.

Apstrakt

Uvod. U ovom slučaju prikazano je vođenje anestezije kod porodilje sa spinalnom mišićnom atrofijom tip II, kod koje je urađen elektivan carski rez u neurooksjalnoj anesteziji. **Prikaz slučaja.** Žena, stara 33 godine, kojoj je ovo bila prva trudnoća, u 39-oj nedelji gestacije bila je planirana za carski rez zbog placente previje. U anamnezi je imala spinalnu mišićnu atrofiju tip II, korektivnu operaciju kifoskolioze, i bila je vezana za invalidska kolica. Odluka da se radi u kombinovanoj spinalno-epiduralnoj anesteziji donešena je zbog prisustva prediktora za otežanu intubaciju (ograničeno otvaranje usta, ograničena pokretljivost vratne kičme). Haringtonove šipke i ožiljno tkivo komplikovali su primenu kombinovane spinalno-epiduralne anestezije, ali je anestezija ipak uspešno primenjena. **Zaključak.** Spinalna mišićna atrofija u trudnoći veoma je retka i predstavlja veliki izazov za anesteziologa zbog respiratorne disfunkcije, očekivane otežane intubacije, teške kifoskolioze i ograničenja u primeni neuromišićnih relaksanata. U radu su prikazani potencijalni rizici koje treba uzeti u obzir prilikom primene anestezije za carski rez kod porodilja sa spinalnom mišićnom atrofijom.

Ključne reči:
porođaj; carski rez; distrofija, miotonička; anestezija,
epiduralna; anestezija, spinalna.

Introduction

Spinal muscular atrophy (SMA) was first described by Austrian and German neurologists, Werdnig and Hoffman in the 19th century¹. SMA is a neuromuscular disease that is accompanied by degeneration of alpha motor neurons of the spinal cord, resulting in progressive proximal muscle weakness and paralysis¹. Disruption of the survival motor neuron 1 gene

on chromosome V causes SMA in about 95% of the patients¹. The incidence of SMA is 1 : 6,000 to 1 : 10,000 live births². There are four types of SMA dependent on age of onset and severity of clinical features (Table 1)³. Diagnosis is confirmed using molecular genetic analysis, electromyography and muscle biopsy. There is yet no cure for the condition⁴. Pregnancy in women with SMA is rare and management can be challenging for obstetric and anesthesiology teams involved⁵.

Table 1**Classification and clinical characteristics of spinal muscular atrophy³**

Types	Age of onset	Clinical features	Average survival
Acute infantile form (Werdnig–Hoffman disease) – type I	< 6 months	Severe muscle weakness, hypotonia, bulbar dysfunction, spinal deformities, respiratory failure	Bad (< 2 years)
Chronic infantile form (intermediate) – type II	6–18 months	Moderate muscular weakness, susceptibility to respiratory infections, spinal deformities, supportive sit but never stand	Middle (10–40 years)
Chronic juvenile form (mild, Kugelberg–Welander disease) – type III	> 18 months	Mild to moderate muscular weakness, mild restrictive lung disease, may or may not have spinal deformities, walk during adulthood	Normal life span
IV (adult)	> 30 years	Mild muscular weakness, mild weakness in arms and legs, walk unaided	Normal life span

There is no description in literature on the effects of SMA on uterine musculature, but since the uterus is autonomically innervated, it is anticipated to have a normal contraction strength and pattern result in a vaginal delivery 6. However, labor may not be effective and majority of patients with SMA are delivered via cesarean section 7, 8. Hereby we presented a case of an anesthetic management of a patient with SMA type II who underwent elective cesarean section with neuraxial anesthesia.

Case report

A 33-year-old woman, G1-parity-P0, at 39 weeks of gestational age was scheduled for a cesarean section due to central placenta *previa*. She had a history of SMA type II, the diagnosis which was based on electromyographic reports and clinical progression of symptoms. Her symptoms included muscle weakness that began when she was 11 months old, when she presented as a “limp baby”. The patient’s motor development was slow and she started to walk when she was 3 years old, always aided. At the age of 5–6 years, she was diagnosed with kyphoscoliosis and this was presumed to be a result of the disease progression involving muscle weakness of the trunk and extremities. When she was 9 years old, she underwent surgical correction of kyphoscoliosis with insertion of Harrington rods. She remained wheelchair-bound following the surgery due to muscle weakness. The patient had never undergone a muscle biopsy or had any genetic testing performed and there was no family history of neuromuscular disease. During her pregnancy she did not describe any deterioration in her symptoms or signs of SMA.

Preoperative biochemical, hematologic and blood gas analysis were within normal limits. Her body mass index was 25 kg/m² (weight 68 kg, height 1.65 m). The patient had predictors for a difficult intubation, which included: Mallampati class 4 (Figure 1); reduced mouth opening to 10 mm; thyromental distance < 6 cm; and reduced neck flexion (Figure 2). She did not describe any bulbar muscle weakness, however, she was prone to respiratory infections prior to pregnancy (the patient was a smoker). The patient was the American Society of Anesthesiologists (ASA) class 3. The decision was made to proceed with a scheduled cesarean section and the needle-through-needle combined spinal-

epidural (CSE) anesthesia technique was chosen as the safest and most appropriate mode of anesthesia due to predictors of difficult intubation. Preoperative vital signs were within normal limits (oxygen saturation 98% on air, respiratory rate 15/min, heart rate 88/min, blood pressure 125/70 mm Hg).

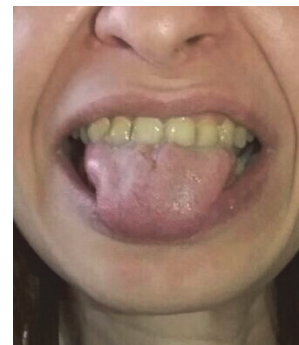


Fig. 1 – Predictors of a difficult airway with our patient: Mallampati class 4.

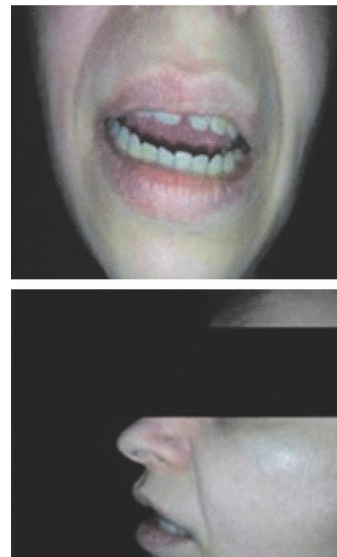

Fig. 2 – Predictors of a difficult airway with our patient: reduced mouth opening.

Preoperatively, two large-bore peripheral intravenous (IV) cannulas (16 G) were placed and the patient received ranitidine 50 mg i.v., ondansetron 4 mg i.v., and dexa-

methasone 4 mg i.v. A CSE procedure was performed in the sitting position at the L3/4 interspace using a loss of resistance technique with saline [Perican® 18G Tuohy needle, Pencan® 27 G spinal needle, Perifix® 20 G nylon epidural catheter, Espocan® docking system (B. Braun Medical Inc. Melsungen, Germany)]. Placement of the CSE took three attempts due to presence of scar tissue and Harrington rods (Figure 3). Depth of the epidural space from skin was 4 cm. Intrathecal drug administration consisted of 0.5% isobaric bupivacaine 12 mg and fentanyl 25 µg. Sensory block height to dermatomal level T4 was confirmed bilaterally prior to commencement of surgery. The patient was positioned supine with left uterine displacement. The patient's cardiovascular status remained stable throughout surgery, and the surgery proceeded without any complications (duration 55 minutes). A healthy female infant was delivered: weight 2,850 g; length 47 cm; head circumference 33 cm. Apgar score at 1 minute and 5 minutes was 10/10. Intraoperative fluids consisted of Ringer's lactate solution 1,500 mL and hydroxyethyl starch 500 mL, and estimated blood loss was 500 mL. The patient was transferred to the intensive care unit postoperatively for monitoring. Postoperative analgesia included intermittent 4 mL boluses *via* the epidural catheter (0.25% bupivacaine + fentanyl 5µg/mL) and diclofenac 75 mg intramuscularly as required [if the Visual Analogue Scale (VAS) \geq 3/10]. On the postoperative day 1 the patient received 5 × 4 mL boluses *via* the epidural catheter in addition to two doses of diclofenac. Pain control was deemed satisfactory and her VAS never exceeded 3/10. There were no reported incidences of nausea, vomiting, pruritis, or urinary retention and there was no evidence of disease progression. The patient had a delayed discharge (on the postoperative day 8) due to physiological jaundice in the neonate. At 3 years of age the child did not exhibit any symptoms or signs of the neuromuscular disease.

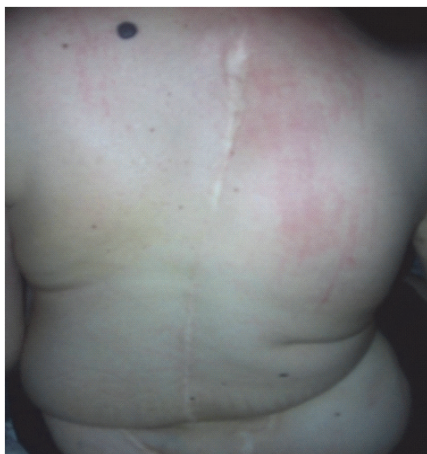

Fig 3. – Post-corrective surgery for thoracolumbar kyphoscoliosis of our patient.

Discussion

There are rare descriptions of anesthetic management of a patient with SMA type II with predictors for a difficult intubation. In this case the various anesthetic options for

labor analgesia and surgical anesthesia and the risks and benefits of each technique were considered within the multidisciplinary team as well as with the patient, to optimize the safest and best outcome for the patient and her infant. There is limited literature describing anesthetic management of a pregnant women with SMA and both regional blocks and general anesthesia have been used⁷. However, Bollag et al.⁶ present a literature review of 18 case reports describing anesthetic management of patients with SMA. There were 12/18 patients delivered *via* scheduled cesarean section: 7/12 patients received general anesthesia (GA), 4/7 were due to failed neuraxial anesthesia; 4/12 patients received neuraxial anesthesia, 1/4 required a secondary neuraxial technique; 1/12 patients received local anesthetic infiltration and i.v. sedation; 2/18 patients delivered *via* non-scheduled cesarean section and 4/18 patients had vaginal deliveries⁶. In case series of 12 patients with SMA, who delivered a total of 17 infants, obstetric complications were reported in 13/17 (76%) deliveries, and included: premature labor (6/17 deliveries) and preterm delivery (2/17 deliveries); prolonged labor (4/17 deliveries); and prolonged recovery postpartum (6/12 women), cesarean section (3/12). An exacerbation of muscle weakness after the second trimester was noted in 8/12 (67%) of the women, with lasting disability in 5/12 (40%) of the women⁹.

There are several case reports in the literature describing successful placement of neuraxial anesthesia, which include single-shot spinals, spinal catheters and CSE anesthesia techniques¹⁰⁻¹². The presented patient had limited mouth opening and reduced neck extension, so the decision was made to attempt the needle-through-needle CSE technique for surgical anesthesia. Harrington rods and scar tissue complicated placement of the CSE anesthesia, however successful placement was achieved. Neuroaxial anesthesia can be technically difficult. Epidural anesthesia may fail due to unpredictable inadequate spread of local anesthetics, particularly if there had been severe scoliosis and corrective back surgery using Harrington rods, due to scar tissue, and if you use an epidural catheter or continuous spinal catheter allows careful titration to achieve the desired dermatome level⁸. Positioning a wheelchair-bound patient and defining landmarks can be difficult, therefore it may be beneficial to use ultrasound-guidance prior to attempting placement of neuraxial anesthesia⁶. Reported doses administered for spinal anesthesia range from 7.5–14 mg hyperbaric bupivacaine, fentanyl 15–25 µg, and morphine 0.1 mg^{3, 8, 11}. Other options reported for cesarean section include local anesthetic infiltration (0.5% lidocaine 100 mL) supplemented with i.v. sedation (midazolam, morphine and propofol) and occasionally with the addition of oxygen/nitrous oxide, but this technique will not provide a block as dense as with a neuraxial technique^{6, 13}. Ilioinguinal, iliohypogastric and transversus abdominis plane nerve blocks have been used as options for intra- and post-operative pain control^{5, 14}.

General anesthesia in patients with SMA was complicated by underlying restrictive lung disease (RLD), sensitivity to nondepolarizing muscle relaxants, potential for hyperkalemia with succinylcholine and likelihood of difficult intubation¹⁵. It may be necessary to perform an awake fiberoptic intubation

(FOI) if the patient has predictors for a difficult airway^{2, 16}. Dexmedetomidine has been administered for sedation during an awake FOI¹⁷. In patients with SMA there are no contraindications to standard agents for induction of anesthesia and volatile anesthetics for maintenance of anesthesia⁵. The administration of a depolarizing muscle relaxant agent (e.g. succinylcholine) is contraindicated due to chronic denervation that can lead to rhabdomyolysis and severe hyperkalemia^{2, 5, 18}. Nondepolarizing muscle relaxant (NDMR) agents can safely be administered and reversed using neostigmine⁴, however, patients with SMA are sensitive to NDMR drugs and therefore a reduced dose should be administered with close monitoring followed by complete reversal². Some authors recommend avoidance of neuromuscular blockade in patients with SMA, there by intubating without blockade, especially in the presence of preoperative respiratory disorders⁵. The use of sugammadex in a patient with SMA undergoing a cesarean section with GA has not been described in the literature, however it has successfully been used in patient with SMA undergoing GA for laparoscopic cholecystectomy¹⁹. Severe RLD is often present in patients with SMA, and with the additional stress from physiological changes of pregnancy, pulmonary function can be worsen during pregnancy but may improve post-delivery⁹. However, postoperative ventilatory support in the intensive care unit may be necessary due to respiratory weakness^{6, 18}. Intra-

and postoperative analgesia can be achieved using multimodal analgesia regimens, including opioids^{3, 7, 20}.

Based on carefully estimation of overall complex medical conditions and the anticipated difficult intubation in this case, the patient-tailored approach to delivery was made and the needle-through-needle CSE anesthesia technique was chosen.

There are limitations in the consideration of the presented clinacal experience related to anesthetic management of patients with SMA type II undergoing cesarean section, because no generalisations was possible since it was a case study. Thus, further studies and analyses of various options of anesthetic management are needed to provide the evidence of the appropriate choice for safe delivery.

Conclusion

In summary, it is highly recommended that pregnant patients with SMA as high-risk patients have a multidisciplinary team approach to plan for a safe delivery, due to complexities of these cases. There are various anesthetic options for labor analgesia and surgical anesthesia, so the risks and benefits of each technique should be discussed within the highly skilled multidisciplinary team as well as with the patient, to optimize the safest and best outcome for the patient and her infant.

R E F E R E N C E S

1. *D'Amico A, Mercuri E, Tirziano FD, Bertini E.* Spinal muscular atrophy. *Orphanet J Rare Dis* 2011; 6(1): 71.
2. *Flunt D, Andreadis N, Menadue C, Welsh AW.* Clinical commentary: obstetric and respiratory management of pregnancy with severe spinal muscular atrophy. *Obstet Gynecol Int* 2009; 2009: 942301.
3. *Özhan MÖ, Süzger MA, Eşkin MB, Çaparlar C, Atik B, Fener N.* Combined spinal epidural anesthesia for cesarean section in a parturient with spinal muscular atrophy type III. *Anestezi Dergisi* 2012; 20(2): 119–122. (Turkish)
4. *McLoughlin L, Bhagvat P.* Anaesthesia for caesarean section in spinal muscular atrophy type III. *Int J Obstet Anesth* 2004; 13(3): 192–5.
5. *Habib AS, Muir HA.* Tracheal intubation without muscle relaxants for caesarean section in patients with spinal muscular atrophy. *Int J Obstet Anesth* 2005; 14(4): 366–7.
6. *Bollag L, Kent CD, Richebe P, Landau R.* Anesthetic management of spinal muscular atrophy type II in a parturient. *Local Reg Anesth* 2011; 4: 15–20.
7. *Harris SJ, Moaz K.* Caesarean section conducted under subarachnoid block in two sisters with spinal muscular atrophy. *Int J Obstet Anesth* 2002; 11(2): 125–7.
8. *Buettner AU.* Anaesthesia for caesarean section in a patient with spinal muscular atrophy. *Anaesth Intensive Care* 2003; 31(1): 92–4.
9. *Rudnik-Schöneborn S, Zerres K, Ignatius J, Rietschel M.* Pregnancy and spinal muscular atrophy. *J Neurol* 1992; 239(1): 26–30.
10. *Maruotti GM, Anfora R, Scanni E, Rispoli M, Mazzarelli LL, Napolitano R, et al.* Anesthetic management of a parturient with spinal muscular atrophy type II. *J Clin Anesth* 2012; 24(7): 573–7.
11. *Gaca M, Kokot N, Koziolek A, Kuczkowski KM.* Combined spinal epidural anesthesia for cesarean section in a parturient with spinal muscle atrophy type III (Kugelberg-Walendar disease). *J Matern Fetal Neonatal Med* 2011; 24(1): 195.
12. *Howarth L, Glamville T.* Management of a pregnancy complicated by type III spinal muscular atrophy. *BMJ Case Rep* 2011; 2011. pii: bcr1020103402.
13. *Burnett T, Halim M.* Local anesthetic infiltration for cesarean section in a patient with spinal muscular atrophy type II. In: *SOAP 42nd Annual Meeting*; 2010 May 12–16; San Antonio (TX). Abstract 132.
14. *Coffman JC, Fiorini K, Ristev G, Beeston W, Small RH.* Transversus abdominis plane and ilioinguinal/iliohypogastric blocks for cesarean delivery in a patient with type II spinal muscular atrophy. *Int J Obstet Anesth* 2016; 25: 79–81.
15. *Liu X, Wang D, Ma D.* Using General Anesthesia plus Muscle Relaxant in a Patient with Spinal Muscular Atrophy Type IV: A Case Report. *Case Rep Anesthesiol.* 2011; 2011: 743587.
16. *Pugh CP, Healey SK, Crane JM, Young D.* Successful pregnancy and spinal muscular atrophy. *Obstet Gynecol* 2000; 95 (6 Pt 2): 1034.
17. *Neumann MM, Davio MB, Macknet MR, Applegate RL 2nd.* Dexmedetomidine for awake fiberoptic intubation in a parturient with spinal muscular atrophy type III for cesarean delivery. *Int J Obstet Anesth* 2009; 18(4): 403–7.
18. *Kitson R, Williams V, Howell C.* Caesarean section in a parturient with type III spinal muscular atrophy and pre-eclampsia. *Anaesthesia* 2004; 59(1): 94–5.
19. *Stewart PA, Phillips S, De Boer HD.* Sugammadex reversal of rocuronium-induced neuromuscular blockade in two types of neuromuscular disorders: Myotonic dystrophy and spinal muscular atrophy. *Rev Esp Anesthesiol Reanim* 2013; 60(4): 226–9.
20. *Fang Q, Gao G, An J, Liu C, Qian X, Wen H et al.* Total intravenous anesthesia for cesarean section in a pregnant woman with spinal muscular atrophy. *Chin Med J* 2014; 127(18): 3350–1.

Received on February 24, 2018.

Revised on March 30, 2018.

Accepted on April 12, 2018.

Online First April, 2018.